


Contents lists available at [ScienceDirect](https://www.sciencedirect.com)

Musculoskeletal Science and Practice

journal homepage: www.elsevier.com/locate/msksp

Masterclass

Eagle's syndrome, elongated styloid process and new evidence for pre-manipulative precautions for potential cervical arterial dysfunction

Andrea M. Westbrook^{a,*}, Vincent J. Kabbaz^b, Christopher R. Showalter^c

^a Method Manual Physical Therapy & Wellness, Raleigh, NC, 27617, USA

^b HEAL Physical Therapy, Monona, WI, USA

^c Program Director, MAPS Accredited Fellowship in Orthopedic Manual Therapy, Cutchogue, NY, 11935, USA



ARTICLE INFO

Keywords:

Eagle's syndrome
Styloid
CAD
Carotid
Autonomic
Manipulation

ABSTRACT

Introduction: Safety with upper cervical interventions is a frequently discussed and updated concern for physical therapists, chiropractors and osteopaths. IFOMPT developed the framework for safety assessment of the cervical spine, and this topic has been discussed in-depth with past masterclasses characterizing carotid artery dissection and cervical arterial dysfunction. Our masterclass will expand on this information with knowledge of specific anatomical anomalies found to produce Eagle's syndrome, and cause carotid artery dissection, stroke and even death.

Eagle's syndrome is an underdiagnosed, multi-mechanism symptom assortment produced by provocation of the sensitive carotid space structures by styloid process anomalies. As the styloid traverses between the internal and external carotid arteries, provocation of the vessels and periarterial sympathetic nerve fibers can lead to various neural, vascular and autonomic symptoms. Eagle's syndrome commonly presents as neck, facial and jaw pain, headache and arm paresthesias; problems physical therapists frequently evaluate and treat.

Purpose: This masterclass aims to outline the safety concerns, assessment and management of patients with Eagle's syndrome and styloid anomalies. By providing evidence of this common anomaly found in almost one-third of the population, hypothesis generation and clinical reasoning with patients presenting with head and neck symptoms can improve.

Implications: Including styloid anomalies as potential hypotheses for patients with head and neck complaints can assist therapists in safe practice and expedite referral. The authors recommend updating the IFOMPT framework to incorporate Eagle's syndrome, a comprehensive autonomic assessment, and palpation of the stylohyoid complex to avoid potentially serious complications from conceivably hazardous interventions.

1. Introduction

Safety with cervical interventions is of paramount importance with carotid artery dissections being a major concern, however the exact mechanisms of some dissections remain unclear. Although controversially rare, particular patients are still more susceptible to these adverse injuries despite screening techniques utilized to safeguard patients. Unreliable reporting of adverse reactions compounds the uncertainty of this problem with underreporting driving cervical arterial dysfunction (CAD) prevalence higher than we realize (Ernst, 2004).

Carotid artery dissection, transient ischemic attack (TIA), stroke and death are the worst-case scenarios when providing interventions to the cervical spine. Clinical priority is to cause no harm to the patient, which

is why this topic has been repeatedly researched and updated over the years (Kerry and Taylor, 2006; Thomas, 2016) and why the International Federation of Orthopedic Manipulative Physical Therapists (IFOMPT) developed the safety framework for CAD (Rushton et al., 2014).

Risk of carotid artery dissection is elevated by just the presence of an elongated styloid process (Raser et al., 2011). Because almost one-third of the population (Ramadan et al., 2007) and three out of four people with temporomandibular disorder (TMD) are believed to have an elongated styloid (Krohn et al., 2018), it is important for clinicians to be able to detect patients who may have this condition, and for IFOMPT to include Eagle's syndrome and styloid process anomalies in their safety framework.

* Corresponding author.

E-mail addresses: awestbrook@methodmanualpt.com (A.M. Westbrook), vjkabbaz@HealWisconsin.com (V.J. Kabbaz), chris@ozpt.com (C.R. Showalter).

<https://doi.org/10.1016/j.msksp.2020.102219>

Received 29 February 2020; Received in revised form 30 May 2020; Accepted 4 July 2020

Available online 25 July 2020

2468-7812/© 2020 Elsevier Ltd. All rights reserved.

This article outlines the safety concerns, assessment and management of patients with Eagle's syndrome. Included online is a case study describing clinical reasoning of a patient with undiagnosed Eagle's syndrome based on abnormal palpatory findings and progression of adverse symptoms.

2. Eagle's syndrome

Eagle's syndrome is a complex symptom assortment produced by provocation of the carotid space structures by anomalies of the styloid process (Eagle, 1948), including an elongated styloid of 30 mm or larger (Correll et al., 1979) (Fig. 1), insulating angulation, calcification of the stylohyoid or stylohyoid ligaments, and/or approximation of the styloid to C1 transverse process, commonly seen with a styloid of normal length (Ho et al., 2015).

The complicated clinical presentation of Eagle's syndrome can be difficult to discern and can take years to diagnose (Ho et al., 2015). Most patients pursue numerous diagnostic tests and imaging to rule out other diagnoses, as many medical providers have never heard of Eagle's syndrome. The presentation can span multiple medical specialties, but is commonly diagnosed by otolaryngologists, orofacial pain specialists, dentists, neurologists and emergency department physicians.

Eagle's syndrome, categorized initially by Dr. Watt Eagle, divides patients into two groups based on the structures compressed or irritated by the styloid complex. The classic form involves cranial nerves 5-trigeminal, 7-facial, 9-glossopharyngeal, and/or 10-vagus, and the vascular form involves the internal carotid artery (ICA), external carotid artery (ECA) (Eagle, 1948), periarterial sympathetic nerve plexus (Eagle, 1949), and more recently in the literature, the internal jugular vein (IJV) (Dashti et al., 2012). Appendix A lists the neural and vascular structures commonly compromised by Eagle's syndrome, along with their function and possible symptoms when injured.

3. Anatomy

3.1. Styloid anatomy

The styloid processes are thin projections of bone at the base of both sides of the skull nestled between the ICA and ECA (Eagle, 1958). The stylomandibular and stylohyoid ligaments (Fig. 2) span down from the distal styloid to the mandibular angle and hyoid bone respectively, and with Eagle's syndrome have been found to calcify or mineralize (Correll et al., 1979). With this ligamentous calcification, symptomatic limitations in the mobility of the jaw, skull, and hyoid bone can ensue (Dayal

et al., 1971; Maki et al., 2018).

The styloid lies posteromedially to the temporomandibular joint (TMJ), and links have been established between the elongated styloid and TMJ (Costantinides et al., 2013). A 2018 study identified 72% of 192 patients diagnosed with TMD had an elongated styloid process with mean length of 40.8 mm (Krohn et al., 2018), well above normal (Correll et al., 1979).

Bony approximation of the styloid to C1 transverse process and osteophytes in the upper cervical vertebrae commonly contribute to Eagle's syndrome (David et al., 2014; Ho et al., 2015). Muscular compression can also contribute to Eagle's syndrome, specifically the digastric and stylopharyngeus (Table 1). Dissection can occur when the artery or vein is injured by styloid proximity (Eraslan et al., 2017).

3.2. Arterial anatomy

Symptom production in both the classic and vascular forms of Eagle's syndrome is commonly reported with head turning (Waters et al., 2019). The ICA is fixated by bone above C1 (Ringel et al., 1977), and investigative studies of the geometrics and morphology of the carotid bifurcation and ICA show that as the head turns, evident changes of the angles of these vessels occur, along with changes in the hemodynamics and amount of stress on various aspects of the arterial wall (Fig. 3) (Papaharilaou et al., 2013).

More research is needed to view the geometrics and morphology of these vessels when the neck provocatively extends, (Rivett et al., 1999). Raser et al. determined the presence of an elongated styloid heightens the risk for arterial dissection (Raser et al., 2011). Eagle's syndrome has been implicated in over 30 documented cases of carotid dissection, many with precipitating neck movements (Table 2). With a fixated carotid artery superiorly (Fig. 4), determining the amount of superior excursion of the carotid bifurcation and where these vessels lie in proximity to each other during neck extension would be helpful to determine if they contact the elongated styloid process or stylohyoid ligament.

3.3. Neural anatomy

Eagle's syndrome commonly involves cranial nerves 5, 7, 9, and 10. Appendix A describes the function of these nerves, along with their clinical presentation upon injury.

A woven plexus of parasympathetic and sympathetic nerve fibers encircles the carotid arteries called the periarterial sympathetic nerve plexus, or carotid plexus (Fig. 5). This carries communications from the

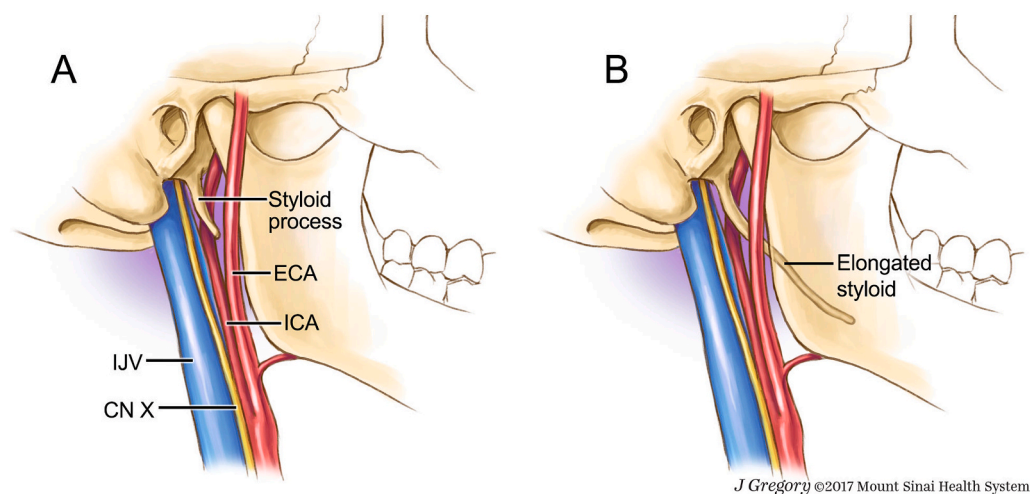


Fig. 1. Fig. 1A. Illustration of normal length styloid process and associated vascular and neural structures. Fig. 1B. Illustration of elongated styloid process traveling just proximal to the carotid bifurcation through the carotid arteries as seen in many patients with Eagle's syndrome. (Illustrations A & B are printed with permission from ©Mount Sinai Health System, provided by senior illustrator Jill Gregory (Badhey et al., 2017). ICA = Internal carotid artery. ECA = External carotid artery. IJV = Internal jugular vein. CN X = Cranial nerve 10 – Vagus nerve.

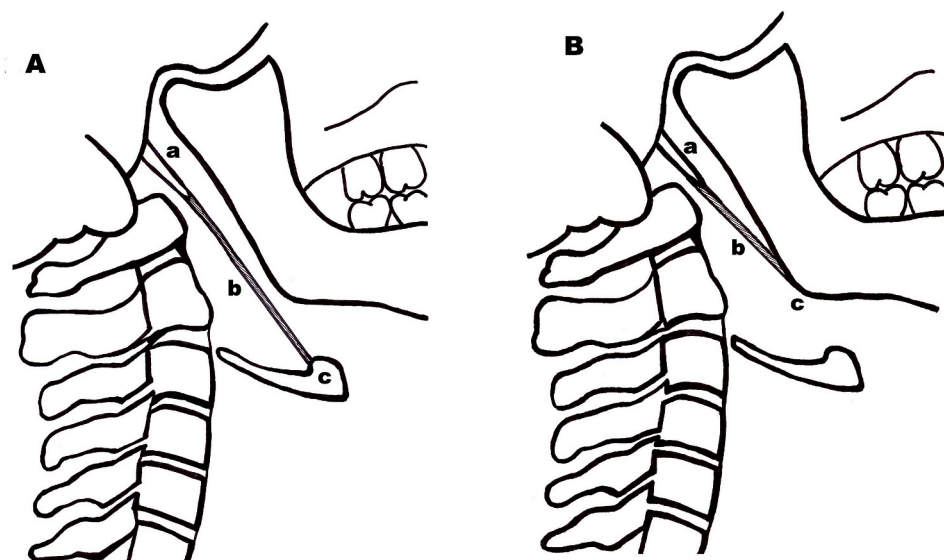


Fig. 2. Fig. 2A. Lateral illustration of the stylohyoid ligament. Anatomy includes: a.) Normal sized styloid process, shorter than 1/3 the ramus length (Goldstein and Scopp, 1973). b.) Stylohyoid ligament. c.) Hyoid bone. Fig. 2B. Lateral illustration of the stylo-mandibular ligament. Anatomy includes: a.) Styloid process. b.) Stylo-mandibular ligament. c.) Mandible. The stylo-mandibular ligament can present as an extension of the deep cervical fascia (Frommer, 1974). The stylohyoid and stylo-mandibular ligaments have been found to partially or fully calcify/mineralize with Eagle’s syndrome (Correll et al., 1979), and are part of the styloid complex.

Table 1

Risks associated with Eagle’s syndrome. **Bony Risks.** < 10 mm styloid to C1 approximation found in surgical patients with Eagle’s syndrome (Frommer, 1974; Ho et al., 2015). Styloid to ICA proximity of ≤5 mm heightened the risk of ICA dissection in patients (Eraslan et al., 2017). **Muscular Risks.** Stylopharyngeus compressed the ICA 30–50% in 12.5% of those tested, and caused 55–75% ICA compression when the head was rotated ipsilaterally (Tubbs et al., 2010). Digastric muscle caused moderate to severe compression of the IJV in 24.1% of those tested (Jayaraman et al., 2012).

Anatomy	Normal Distance	Symptomatic/Unsafe Distance	Author Year
Styloid to C1	>10 mm	0.5–4.6 mm	Ho et al. (2015) Frommer (1974)
Styloid to ICA	7–8 mm	≤5 mm	Yilmaz et al. (2015) Eraslan et al. (2017)

Muscle Anatomy	% of Population	% of Vessel Compression	Author Year
Stylopharyngeus to ICA	12.5%	30–50%	Tubbs et al. (2010)
Digastric to IJV	24.1%	51–100%	Jayaraman et al. (2012)

carotid sinus nerve, glossopharyngeal nerve, vagus nerve, sympathetic trunk, hypoglossal nerve, ansa cervicalis (Porzionato et al., 2019), and facial nerve with somatosensory afferents to the trigeminal nuclei including sensation from the ICA (Khonsary et al., 2013; Nturibi and Bordoni, 2020).

Extrinsic compression of this carotid plexus can produce symptoms of autonomic and vascular nature including vasovagal responses from the elongated styloid or even just the fibrous (non-osseous) stylohyoid complex as confirmed in one case of death by vasovagal response (Ruwanpura et al., 2008). This makes the stylohyoid complex an integral part of assessment when autonomic symptoms occur.

3.4. Venous anatomy

The IJV can also be extrinsically compressed or injured by styloid anomalies. The styloid process and digastric muscle can compress the

vein into the adjacent upper three cervical vertebrae (Jayaraman et al., 2012). This can lead to venous outflow obstruction creating many symptoms of Eagle’s syndrome, including venous stasis and thrombosis (Dashti et al., 2012). Similar dysfunctional venous hemodynamics have been documented in cases of Eagle’s syndrome, multiple sclerosis (MS) (Dashti et al., 2012; Zamboni, 2006) and migraine (Chung et al., 2010). Some patients with IJV obstruction required styloidectomies, along with subsequent jugular stenting for full symptom alleviation (Higgins et al., 2016).

4. Eagle’s syndrome presentation

4.1. Incidence

Incidence of styloid anomalies and elongation is controversial. Prior to 1971, incidence ranged from 4 to 28% (Eagle, 1949; Kaufman et al., 1970). Improved imaging techniques have recently found 30–36% incidence in 1360 patients when including elongated styloids and calcifications of the styloid ligaments (Eraslan et al., 2017; Keur et al., 1986; Ramadan et al., 2007). Not all patients with styloid anomalies are symptomatic, but underestimation of the incidence of Eagle’s syndrome is likely (Piagkou et al., 2009), as documented cases exist in patients with normal styloid length, and extrinsic IJV compression (Ho et al., 2015).

4.2. Aetiology

Cause is unclear (Piagkou et al., 2009), but predisposing factors to symptomatic Eagle’s syndrome have included history of motor vehicle accident (Ho et al., 2015), tonsillectomy (Waters et al., 2019), heredity (Morrison et al., 2012), endocrine changes including menopause (Prasad et al., 2002) and pregnancy (Westbrook et al., 2019). Key findings of patients with Eagle’s syndrome include: mean age 41 (Ceylan et al., 2008) to 46 years, female 69%, and Caucasian 91% (Waters et al., 2019).

5. Patient interview

A thorough subjective examination is critical to recognize patients with Eagle’s syndrome. Presentation of symptoms in any individual case can include one symptom or a plethora of symptoms, with a variety of pain mechanisms involved.

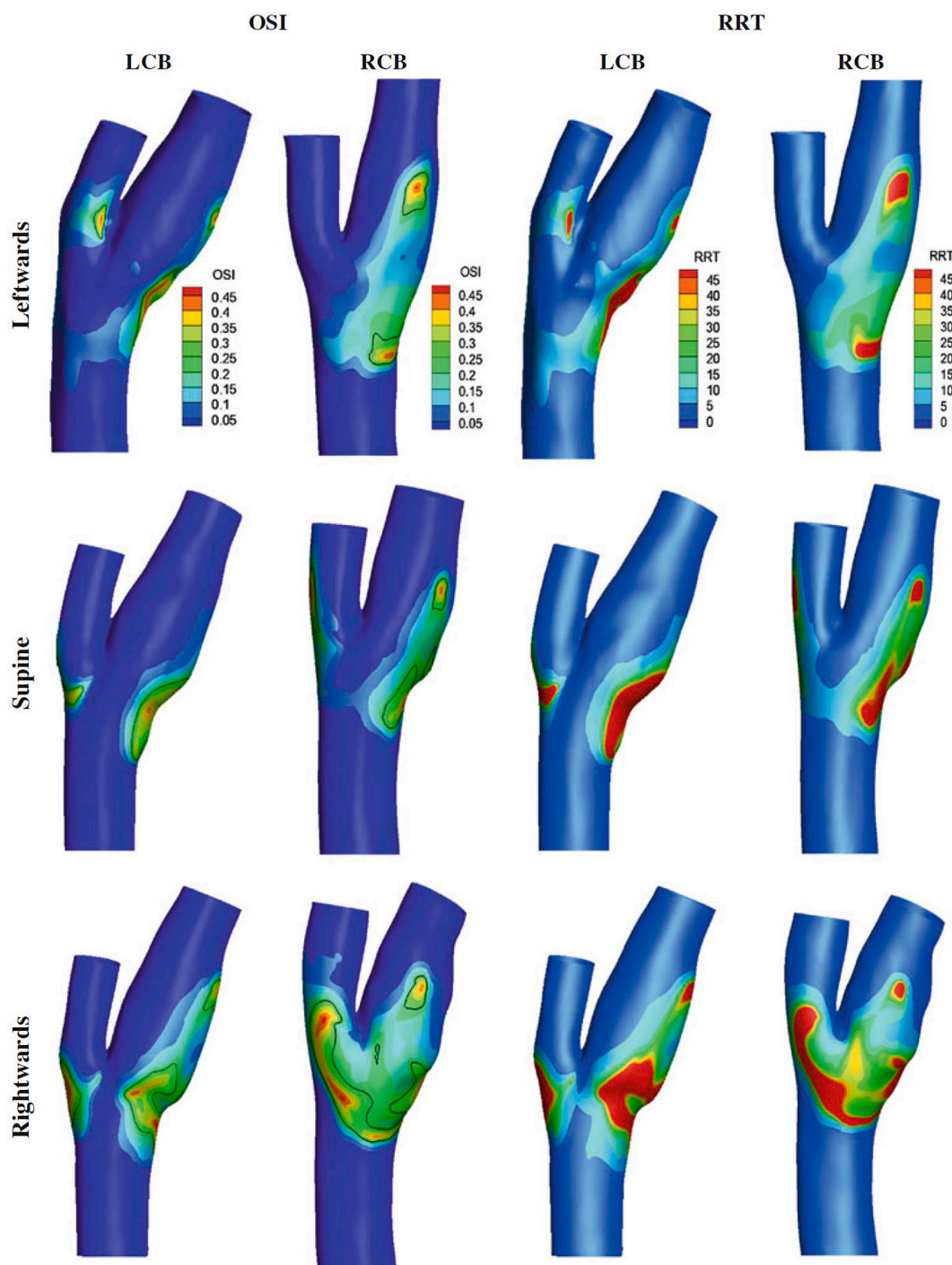


Fig. 3. Contour plots of time-averaged oscillatory shear index (OSI) (areas of unfavorable hemodynamics) and relative residence time (RRT) for the left and right carotid in the neutral, left and right rotated head position for one subject. One can see the changes in the angles and cross-sectional area of the carotid vessels and bifurcation as the head rotates (although this is subject specific). RCB = Right carotid bifurcation. LCB = Left carotid bifurcation. Reprinted by permission from Springer Nature and Copyright Clearance Center: Springer Nature. Medical & Biological Engineering & Computing. (Papaharilaou et al., 2013). Copyright 2020.

5.1. Classic form

The classic form of Eagle's syndrome commonly presents as pain/paresthesia in the neck, jaw/face, head, throat, ear, teeth, tongue, globus sensation, eye twitching (Waters et al., 2019), hoarseness or change in voice, and/or cranial nerve injury/irritation (Kawasaki et al., 2012). Many providers believe this neuralgia is a type of entrapment syndrome involving the cranial nerves, commonly after tonsillectomy (Shin et al., 2009).

5.2. Vascular form

The vascular form of Eagle's syndrome commonly presents as pain/paresthesia in the neck, jaw/face, head (Eagle, 1948), shoulder 'coat hanger syndrome' (Thoenissen et al., 2015), tinnitus, ear muting/fullness (Waters et al., 2019), facial droop/palsy (Galletta et al., 2019), slurred speech or difficulty speaking, extremity tingling/numbness or mono/hemiparesis, visual changes, amaurosis fugax, aneurysm, carotid artery dissection, stroke (Ogura et al., 2015), TIA, syncope/presyncope,

Table 2

ICA dissections in patients with elongated styloids, precipitated by 1.) cervical massage, 2.) cervical movements or 3.) exercise.

Diagnosis	Cause	Age/ Sex	Styloid length	Symptoms/Signs	Author /Year
1. Massage Incidents:					
B ICA dissection, aneurysm	Vigorous neck massage	57 Male	elongated	L neck pain into head, unsteady gait, TIA, aphasia, hemiparesis	Todo et al. (2012)
R ICA dissection	Cervical Massage	55 Male	R 33.3 mm	L hemiplegia, stiff neck, sensory disturbance, hemispacial neglect	Ogura et al. (2015)
L ICA dissection	Deep tissue massage	42 Female	R 60 mm L 45 mm	R hemiparesis, facial weakness and aphasia	Qureshi et al. (2019)
2. Neck Movement Incidents:					
R ICA dissection	Suddenly looking up to ceiling while talking on phone	47 Female	R 42 mm	Slurred speech, L arm tingling, sensory loss, weakness. L neck pain into eye with turn head L, L facial droop	Subedi et al. (2017)
B ICA dissection	Repeated vomiting with hyperflexion of neck	46 Male	R > 40 mm L > 40 mm	L hemiplegia	Torikoshi et al. (2019)
B ICA dissection	Intense jerky head movements dancing “like an invertebrate”	60 Male	R 44 mm L 55 mm	Sudden L hemiplegia, R fronto-orbital HA, confusion, hemiataxia, L lateral hemianopia, Horner’s syndrome, L ptosis	Faivre et al. (2009)
B ICA Dissection	Repeated tonic clonic seizures the 3 months prior	40 Male	elongated	R hemiparesis and dysphagia, L reversible hemiparesis	Jelodar et al. (2018)
L ICA dissection	Sustained L lateral flexion neck phone call	43 Male	elongated L to level of C1/2	L transient monocular blindness, L pulsatile tinnitus and motor aphasia	Zuber et al. (1999)
R ICA dissection	Sustained R lateral flexion neck holding newborn to sleep	41 Female	R 30 mm L 26.6 mm	Sudden R eye blindness	Soo et al. (2004)
R ICA dissection	ICA compression by styloid induced by neck rotation	51 Male	elongated	R orbital pain, Horner’s syndrome	Yamamoto et al. (2013)
B ICA dissection	ICA compression by styloid induced by head tilt and neck extension	46 Male	elongated	Transient aphasia and L visual disturbance, 2 year globus history	Takino et al. (2018)
3. Exercise Incidents:					
R ICA dissection	Exercise “chin up” repetition with head forcibly turned to L	41 Male	R 45 mm L 50 mm	L hemiparesis, hemineglect, L visual field neglect	Razak et al. (2014)
R ICA dissection	Intensive physical exercise at gym (boxing)	41 Female	elongated	Sudden severe HA R temple, episodes of L arm numbness	Sveinsson et al. (2013)

dizziness (Todo et al., 2012), and pseudotumor cerebri (Ho et al., 2015). Production of these symptoms can occur from injury or compression of the periarterial nerve plexus, blood vessels or a combination (Eagle, 1949).

5.3. Autonomic symptoms in Eagle’s syndrome

Autonomic dysfunction is not a commonly recognized feature of Eagle’s syndrome, but with completion of an in-depth analysis of the Eagle’s syndrome literature, the authors identified a multitude of associated autonomic symptoms. These include ear fullness, tinnitus, nasal/facial congestion, yawning, headache (Waters et al., 2019), dysphonia/hoarseness, salivation changes, peristalsis dysfunction/gastrointestinal disorders (Scavone et al., 2019), dizziness, syncope/presyncope, hyper/hypotension, cardiac arrhythmias, dyspnea, vagal cardiac inhibition (Ruwana et al., 2008), chest pain (Shenoi, 1972), Horner’s syndrome (Bensoussan et al., 2014), seizures (Malik et al., 2015), venous stasis/swelling, sweating/tearing changes, migraine, fatigue, intolerance to hot/cold, light, alcohol, and stress (Robertson et al., 1994; Westbrook et al., 2019).

5.4. Differential diagnosis

As evidenced by the symptom presentations above, overlap with symptoms of vertebrobasilar insufficiency (VBI), upper cervical instability and cranial nerve palsy are common and must be physically assessed with the safety of the patient in mind when testing the vascular hypothesis. Table 3 displays other differential diagnoses.

The IFOMPT framework describes an appropriate history assessment for risk of vascular involvement (Rushton et al., 2014). Essential history concerns for patients with undiagnosed Eagle’s syndrome include: previous bouts of failed manual therapies, a positive history of objective VBI with neck rotation or extension, recent hormonal changes, neck trauma, tonsillectomy, Bell’s Palsy (Westbrook et al., 2019), autonomic symptoms or undiagnosed rheumatic (Zinnuroglu et al., 2008) or

autoimmune disorders (Levy et al., 2017). Thus, examination for other sources of causation is justified when autonomic signs and symptoms are present.

6. Functional limitations

Symptomatic head turning and bending are the most prevalently documented functional limitations (Waters et al., 2019). Other functional limitations include difficulty swallowing, including anterior neck clicking and necessity for repeated swallows (Douglas, 1952; Eagle, 1949). Mouth opening/trismus, speaking, chewing, yawning (Galletta et al., 2019), coughing (Steinmann, 1970), singing (Schmidt, 1951), sleep dysfunction (Li et al., 2019a) and general tongue movements are also commonly problematic with Eagle’s syndrome (Waters et al., 2019). These dysfunctions correlate with tensioning or compression of the involved cranial nerves (Appendix A), and are the most common triggers for arterial compromise for the cervical arteries, involving cervical extension and end range rotation (Rivett et al., 1999).

7. Physical examination

Physical findings of patients with Eagle’s syndrome or styloid anomalies can be obscure. The authors have determined several positive signs common in patients with elongated styloids.

7.1. Observation

Forward head posture (Johnson et al., 2011) and ipsilateral upper cervical shift to the painful side are common (Kapoor et al., 2015), although longer styloid measurements have been found on the opposite side (Ho et al., 2015).

Observation for autonomic/vascular changes or abnormalities is recommended to determine if the patient presents with fatigue, memory problems, concentration difficulty, general unwell feelings, eye tearing/redness/dryness/twitching, sweating changes, skin discoloration or

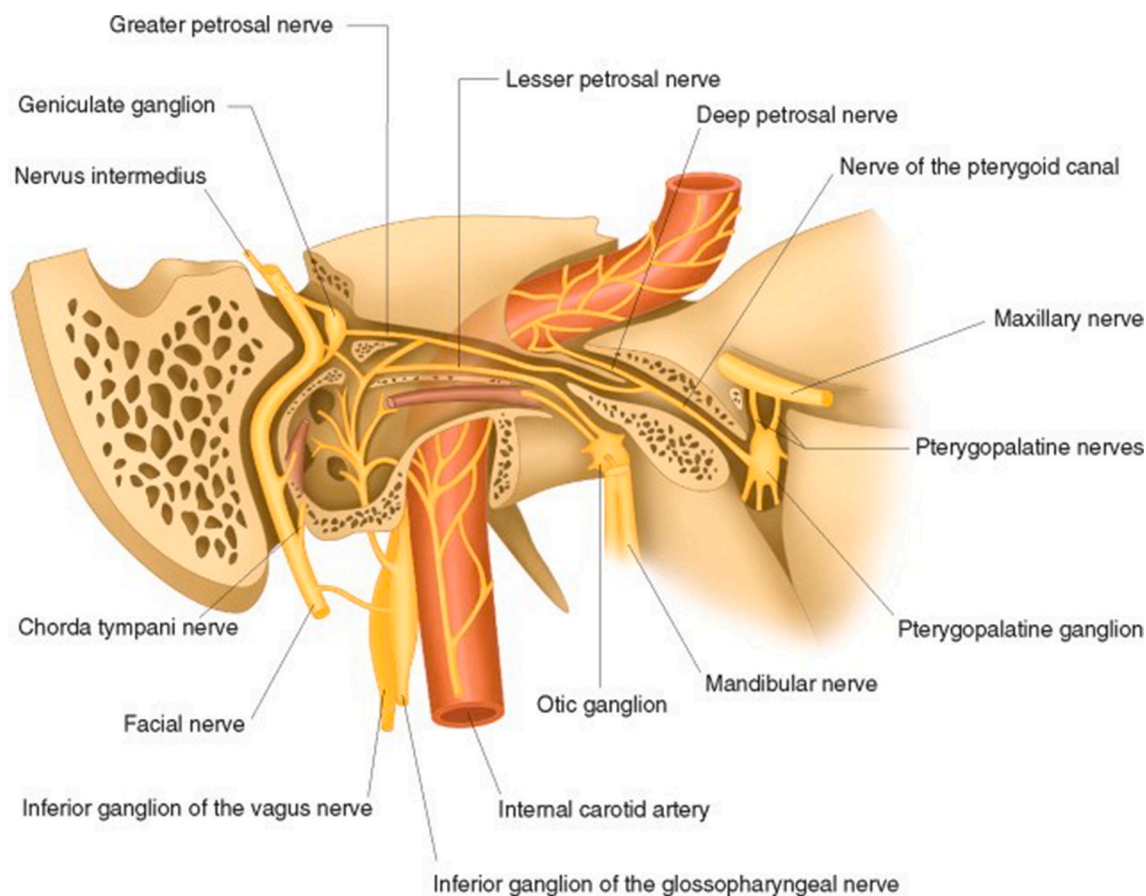


Fig. 4. Intrapetrous branches of the facial nerve. Also imaged is the carotid artery as it courses through the carotid canal of bone, and the carotid plexus encircling the carotid with neural fiber communications from several cranial nerves. Reprinted from *Manual Therapy for the Cranial Nerves*, Jean-Pierre Barral, Alain Croibier, Chapter 19 – Facial Nerve, Pages 153–166, Copyright (2009), with permission from Elsevier and Copyright Clearance Center (2020) (Barral and Croibier, 2009).

patches, anterior neck swelling, ptosis, pupillary changes, facial expression asymmetries, dyspnea, slowed or slurred speech, or expressive aphasia (Robertson et al., 2012; Rushton et al., 2014).

7.2. Mobility testing

Cervical, jaw and hyoid hypomobility are common in patients with Eagle's syndrome. Limited end range cervical (Johnson et al., 2011) and temporomandibular active and passive range of motion may be present (Westbrook et al., 2019). Passive accessory joint hypomobility is common in the upper cervical articulations (Feldman, 2003), TMJ (Westbrook et al., 2019), hyoid (inferiorly and medially) (Willett et al., 2019), first rib, clavicle, and glenohumeral joint. Muscular tension is common in the anterior neck (Johnson et al., 2011), suboccipitals (present study), jaw (Feldman, 2003) and thoracic paraspinals (Green et al., 2014).

7.3. Palpation

Palpation of the styloid is essential in determining abnormalities. Externally it can be palpated just distal to the ear, and anterior to C1 transverse process. Intraoral palpation is assessed through the tonsillar fossa, although styloids under 75 mm can be hard to detect with this method (Hampf et al., 1986).

7.4. Special tests

Appropriate testing for VBI and carotid artery insufficiency is indicated to determine vascular or even autonomic involvement. Minimal

pre-manipulative standards involve rotational and pre-manipulative positional testing (Rivett et al., 2006), but to assess carotid artery involvement that can be present with Eagle's syndrome, the authors recommend testing sustained neck extension.

Assessment of the carotid pulse strength in neck neutral, sitting and supine can be informative (Rushton et al., 2014). The clinician is assessing firstly for positive arterial dysfunction and provocation of symptoms, but also for differences of left and right pulses. The authors have found a fainter pulse on one side, pulse reduction in neck extension and a more superficial even visible pulse on the affected side in some patients with Eagle's syndrome (Budincević et al., 2018; Massey and Massey, 1979). Research is needed to assess this further.

7.5. Implications

The IFOMPT framework for physical examination of the cervical spine includes pre-manipulative positional tests, ligamentous stability tests, dizziness differentiation tests, neurological exam (including cranial nerves), blood pressure and carotid pulse assessment (Rushton et al., 2014). Negative findings for these tests are commonly found in patients with Eagle's syndrome (Green et al., 2014; Westbrook et al., 2019). The authors recommend additional testing of these patients including sustained neck extension ICA positional test (Kerry and Taylor, 2006), external/internal palpation of the stylohyoid complex assessing length, proximity to C1, soft tissue density, as well as mobility of the hyoid, jaw and spine. Of course, the performance of these tests is dependent on the patient's individual irritability and safety contraindications.

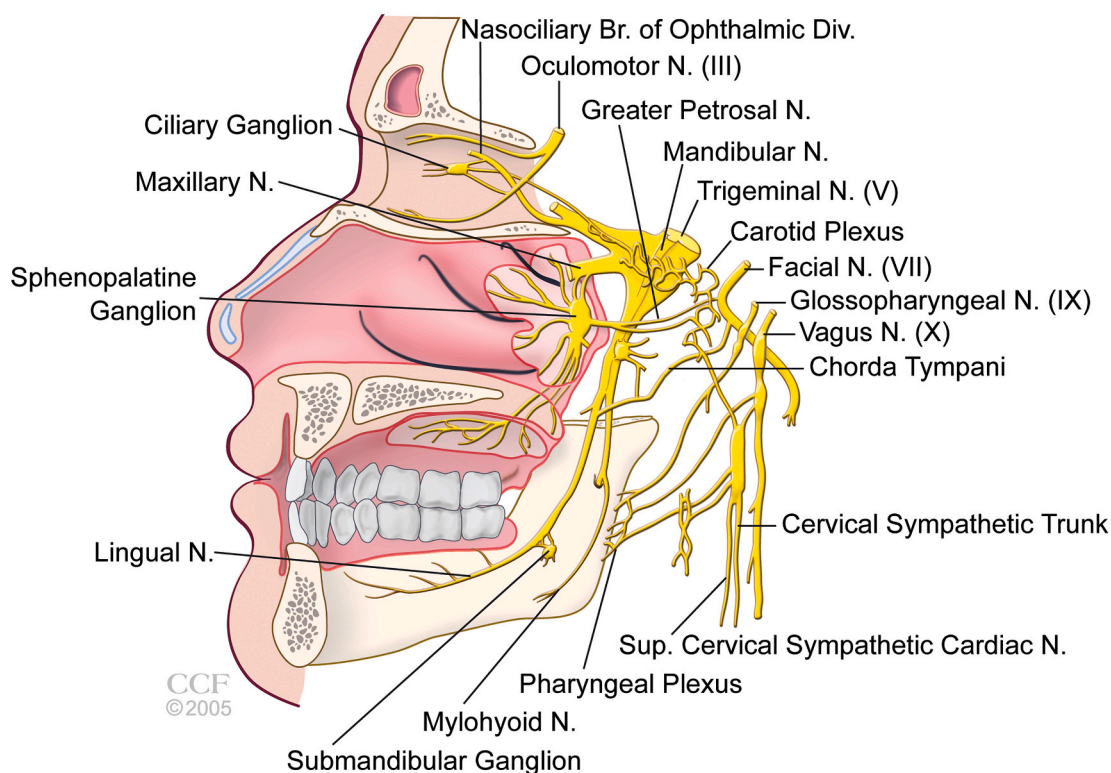


Fig. 5. Sphenopalatine ganglion anatomy. Visible is the carotid peri-arterial sympathetic nerve plexus and its complex cranial nerve communications. Reprinted with permission, Cleveland Clinic Center for Medical Art & Photography © 2005–2020. All Rights Reserved (Khan et al., 2014).

Table 3
Differential diagnoses for patients with Eagle’s syndrome.

Differential Diagnoses	
Cervical radiculopathy	Upper cervical instability
Cervicogenic headache	Tumor
TMD (temporomandibular disorder)	Migraine
Trigeminal autonomic cephalgias	Tear duct based disorder/clogged tear ducts
Sphenopalatine ganglia neuralgia	Sinus disorder/recurrent sinus infections
Vertebrobasilar insufficiency	Cranial nerve palsy/Bell’s Palsy
Carotid insufficiency	Autoimmune diseases
TIA, stroke, aneurysm	Cardiac problems:
Lung disorders: laryngitis, bronchitis, asthma	Mitral valve prolapse and angina

8. Imaging/Diagnostic tests

Referral for medical diagnostic assessment is not standardized when vascular involvement is hypothesized (Rushton et al., 2014), and is determined by the treating clinician based on the clinical presentation of the involved patient. As patients with Eagle’s syndrome can present similarly to patients with positive VBI or cervical ligamentous instability, the authors suggest clinicians continue to refer as previously recommended.

Ultrasound doppler of the cervical arteries and magnetic resonance imaging (MRI) with contrast are commonly used to rule out arterial pathology (Kerry and Taylor, 2006), and frequently will be negative for patients with Eagle’s syndrome (Slavin, 2002).

Chronic microvascular ischemia upon brain MRI with contrast has been shown in patients with Eagle’s syndrome (Aydin et al., 2018; Chuang et al., 2007), as well as in patients with other conditions with similar symptoms and unknown causes such as migraine (Swartz and Kern, 2004), MS (Ge et al., 2005), Sjögrens (Akasbi et al., 2012) and POTS (postural orthostatic tachycardia syndrome) (Umeda et al., 2015).

Research is required to determine if these patients may have a styloid anomaly compromising circulation, and if styloidectomies may be beneficial.

The best studies to detect styloid anomalies are head and neck computed tomography (CT) scans (requesting stylohyoid complex measurements), three-dimensional (3D) CT scans, lateral cervical radiographs, and panoramic dental radiographs (Figs. 6 and 7). Of these four tests, panoramic dental radiographs have lower radioactive exposure compared to the gold standard 3D CT (Nayak et al., 2007), are easily obtainable and simple for a non-radiologist to identify an elongated styloid.

9. Assessment of risk and consent for interventions

It should be noted that not all patients with an elongated styloid have Eagle’s syndrome, but the risk for serious adverse events is heightened by the presence of this anomaly (Raser et al., 2011).

According to the IFOMPT framework, cervical anomalies are a precaution to orthopedic manual therapy interventions. Clinical reasoning is required in the presence of styloid anomalies to determine if physical therapy (PT) is suitable for patients or if the risks outweigh the benefits (Rushton et al., 2014). This would include an appreciation of the patient’s irritability, and if any arterial symptoms exist. If these are easily reproduced, PT may not be appropriate and medical referral warranted. If a lengthened styloid is present without insufficiency symptoms, it may be wise to educate and obtain consent prior to PT interventions.

10. Adverse reactions and safety of interventions

Many patients who unknowingly have Eagle’s syndrome pursue PT, massage, medical management, injections, and surgery (Waters et al., 2019). No research has determined optimal PT treatments for patients with Eagle’s syndrome.

Serious adverse reactions to treatment include: carotid artery

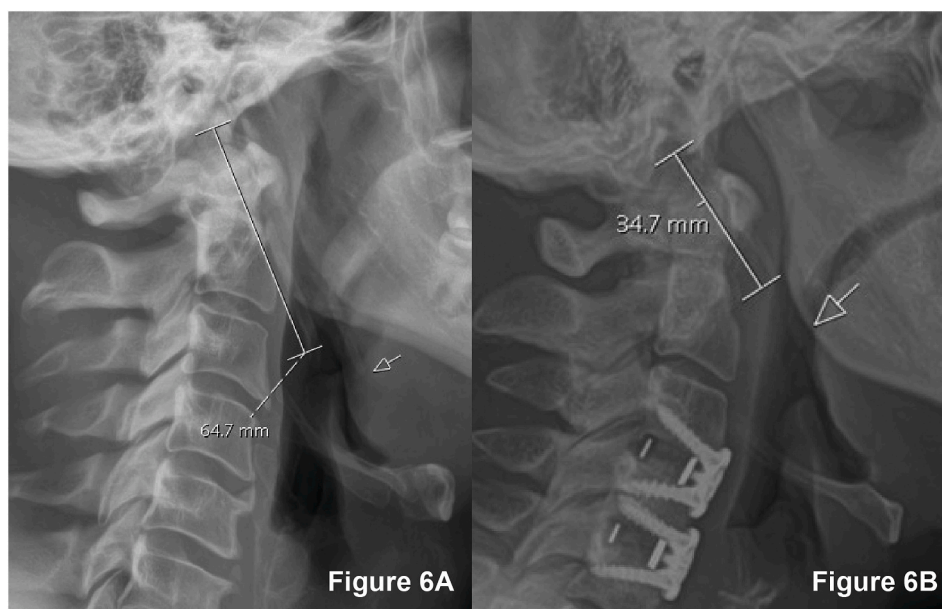


Fig. 6. Lateral Cervical Radiographs of two subjects with elongated styloid processes. **Fig. 6A** has a styloid length of 64.7 mm. The arrow points to the second elongated styloid. **Fig. 6B** has a styloid length of 34.7 mm. The arrow points to calcifications extending down from the styloid toward the hyoid bone.

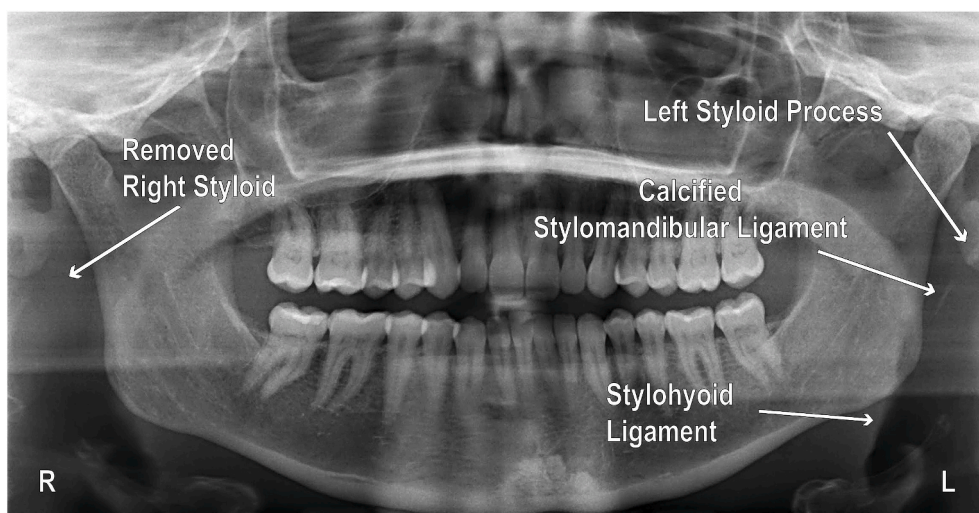


Fig. 7. Panoramic dental radiograph of a patient with Eagle's syndrome after removal of the right elongated styloid complex. The remaining left styloid complex is greater than one-third the ramus length, and therefore considered to be elongated (Goldstein and Scopp, 1973). This elongated styloid was not visualized on the patient's lateral cervical radiograph.

dissection, TIA, stroke, death, and lesser but informative adverse circulatory and autonomic reactions. Four studies describe adverse events after manual therapy: one with production of Horner's syndrome four months after chiropractic manipulation (Chang et al., 2015), the other three with carotid artery dissection and/or stroke after massage (Table 2). Exercise produced adverse symptoms/events including headache, neck and shoulder pain, photophobia, hyperacusis or arterial dissection in three studies (Massey and Massey, 1979; Sveinsson et al., 2013; Thoenissen et al., 2015).

Continuous dialogue with the patient during the intervention is imperative to monitor for adverse symptoms. The authors recommend discontinuation of adverse symptomatic interventions, and at least 24-h monitoring for continuation or worsening of adverse symptoms.

An elongated styloid has been found to be the cause of arterial wall weakening, blood vessel compression (Todo et al., 2012), neural plexus irritation and inflammation in the carotid space (Kawasaki et al., 2012),

all of which heighten the risk for an adverse event (Thomas, 2016). Repeated mobilizations and manipulations could further progress the condition with repeated provocation of the neural and vascular structures (Rushton et al., 2014).

Current research recommends the avoidance of thrust manipulation (Green et al., 2014), along with relative contraindications for direct pressure/massage along the carotid or styloid complex, sustained or repeated end range cervical rotation, extension, lateral flexion, and combined flexion/rotation in patients with styloid anomalies, as these have led to carotid dissection in several cases (Table 2).

11. Treatment interventions

The authors have established common beneficial treatments for patients with Eagle's syndrome presentation, especially regarding the autonomic nervous system. Treatment is dependent on the patient's

Table 4

Eagle's syndrome and elongated styloids have been linked to the conditions listed. A styloid anomaly should be hypothesized and confirmed or negated when evaluating the head, neck or jaw and appropriate precautions taken.

Linked Condition	Author Year	Notes
Aneurysm ICA	Sultan et al. (2019)	3 patients - good post-surgery recoveries
Ankylosing Spondylitis	Levy et al. (2017)	25% of 24 patients had styloids \geq 40 mm
Bell's Palsy	Westbrook et al. (2019)	Facial palsy, epiphora alleviated surgically
DISH	Ho et al. (2017)	30% of 64 patients had styloids \geq 40 mm
End-Stage Renal Disease/Hemodialysis for months	Constantinides et al. (2019)	Mean styloid length 39 mm versus 21 mm in control Abnormal calcium/phosphate metabolism and secondary hyperparathyroidism
Fibromyalgia	Zinnuroglu et al. (2008)	Pain reduction from 6.7 to 2.1 (VAS) after styloidectomies 3 patients abolished symptoms except continued headaches
Horner's Syndrome	Chang et al. (2015)	ICA compression at level of C1 by styloid
Migraine	Zeckler et al. (2012)	Styloid impingement of sympathetic chain
	Chung et al. (2010)	IJV compression aggravates migraine
	Dashti et al. (2012)	IJV compression by styloid process
Motor Vehicle Accident/Whiplash	Ho et al. (2015)	2 cases improved post-surgery
Multiple Sclerosis	Zamboni et al. (2019)	9% of patients with Eagle's syndrome
Myofascial Pain Syndrome	Zinnuroglu et al. (2008)	Pain reduction from 6.7 to 2.1 (VAS) after styloidectomies. 9 patients abolished symptoms except continued headaches
Perimesencephalic Hemorrhage	Zamboni et al. (2019)	26% of patients with Eagle's syndrome
Pseudotumor Cerebri	Ho et al. (2015)	2 cases alleviated surgically
	Dashti et al. (2012)	2 cases alleviated surgically
	Jelodar et al. (2018)	Repeated tonic clonic seizures 3 months
Seizures	Malik et al. (2015)	Repeated tonic clonic seizures
	Torikoshi et al. (2019)	Over 30 cases of stroke caused by elongated styloids in the literature
Stroke/TIA	Krohn et al. (2018)	72% of patients had elongated styloids
TMD	Waters et al. (2019)	31.3% of patients with Eagle's syndrome
Tonsillectomy	Kawasaki et al. (2012)	1 case. 4–5 times annually - improved
Upper Respiratory Infections	Current study	1 case. alleviated surgically

symptoms and correlated objective impairments with constant monitoring for any adverse symptoms or signs. Manual therapy (Feldman, 2003; Willett et al., 2019) targeting the cervical and thoracic spine, ribs, jaw, acromioclavicular, glenohumeral joints, and the associated musculature (Green et al., 2014; Wong et al., 2011) have been found to be beneficial in some patients with Eagle's syndrome. Postural re-education and therapeutic exercise (Green et al., 2014) to improve segmental and neural mobility can also prove to be helpful in some patients. Treatments in neck neutral and thoracic manual therapy can be a prudent way to treat the cervical spine (Cleland et al., 2005) and may benefit patients with Eagle's syndrome.

Treatment techniques targeting activation of the parasympathetic nervous system have been found to reduce symptoms for many of these patients. These could include stress reduction techniques, deep breathing, yoga, cognitive behavioral therapy, biofeedback, relaxing music (Ylikoski et al., 2017), general massage, Guasha (Chinese superficial connective tissue massage) (Wang et al., 2015), superficial connective tissue massage (Holey et al., 2011), meditation, sleep, audio visual entrainment (AVE) and low-grade exercise.

Most authors verify the majority of these patients choose surgery after limited response to conservative care, with a reported 93.4% success rate post-surgically (Ceylan et al., 2008).

12. Referral to specialists

Patients suspected of having Eagle's syndrome may require specialty referral which can be difficult due to the rare ability to diagnose this condition. Many patients seek care from multiple physicians with either no diagnosis or incorrect diagnoses. Otolaryngologist skull-based surgeons are the primary specialists for removal of the styloid complex.

Diagnosis is usually made by: 1. Patient symptomology, 2. Imaging, 3. Intraoral palpation into the tonsillar fossa (only sensitive for styloids longer than 75 mm or medially angled) (Frommer, 1974; Hampf et al., 1986), 4. Lidocaine infiltration into the tonsillar fossa to verify temporary relief of symptoms (Prasad et al., 2002; Singhania et al., 2013), although considered ineffective by some surgeons (Saccomanno et al., 2018).

Medication management typically includes glucocorticoids,

anticonvulsants, nerve medications, pain medications, anti-inflammatories (Badhey et al., 2017), and various injections.

13. Further research

To improve patient safety during upper cervical interventions, further research is necessary, specifically investigating the relationship between neck positions and styloid to ICA, ECA and IJV proximity, carotid pulse changes in neck extension and rotation, and carotid bifurcation morphology changes in neck extension.

Enhanced research is needed to determine if styloid anomalies can be the cause of symptoms in a variety of conditions with vascular and autonomic presentations. Established links have been determined between elongated styloids and TMD, Bell's Palsy, TIA, stroke, aneurysms, seizures, pseudotumor cerebri, MS, fibromyalgia, ankylosing spondylitis and DISH (diffuse idiopathic skeletal hyperostosis) (Table 4). It may be possible some patients with these conditions could benefit from surgical excision of the styloid, especially after failed conservative treatment.

In our supplemental case study, styloidectomies alleviated the autonomic symptoms associated with Eagle's syndrome. If this surgical intervention can relieve autonomic symptoms in one condition, it is possible they could improve autonomic symptoms in other similar conditions with unknown causes. Further research is suggested to discern if Eagle's syndrome or an elongated styloid may be linked to other conditions with autonomic features such as Sjögrens syndrome and POTS. Lastly, enhanced research to determine the most beneficial PT interventions or conservative treatment in this patient population would be advantageous considering an estimated one-third of the population has an elongated styloid (Ramadan et al., 2007).

14. Conclusion

Eagle's is a rare, but underdiagnosed syndrome, with variable, often low-level complaints. The authors highlight the lack of sensitive testing to rule out this sinister pathology, and the need for a highly thorough assessment to exclude autonomic and vascular mechanisms. The authors suggest physical therapists and other healthcare professionals can assist in guiding these patients to ear, nose and throat (ENT) specialists for

proper assessment.

After reviewing the Eagle’s syndrome literature, it is clear this syndrome continues to develop in anatomical knowledge and clinical features. It may be possible the autonomic symptoms are overlooked due to complex somatic, neural and vascular complaints. High probability exists that some patients with Eagle’s syndrome omit symptoms they believe are from a different body system, or unrelated. More comprehensive questioning and assessment are essential for improved hypothesis generation and clinical reasoning when encountering a patient with recalcitrant neck, jaw and head symptoms.

Any clinician who treats the cervical spine, headaches, and TMD should have a clear understanding of the symptoms, signs and functional limitations identified regarding Eagle’s syndrome or styloid anomalies. The authors recommend updating the IFOMPT framework to incorporate Eagle’s syndrome, a comprehensive autonomic assessment, and palpation of the stylohyoid complex. This can improve overall understanding of the precautions and contraindications for beginner to expert clinicians alike. With this presented knowledge, we can reduce potentially serious complications in these higher risk patients, such as carotid artery dissection, from conceivably hazardous interventions like cervical manipulation, repeated or sustained end range cervical treatments and massage along the carotid. Including anomalies of the styloid as potential hypotheses for patients with head and neck complaints can assist therapists in safe practice and expedite referral.

Ethical approval

No ethical approval was needed for a single case study. The authors

complied with ethical standards throughout this research. Written patient consent was obtained.

Funding

This research did not receive any grant from funding agencies in the public, commercial, or not-for-profit sectors.

Declaration of competing interest

All authors have materially participated in the research and/or article preparation. Roles for all authors are described below.

1. Andrea M Westbrook. Conception and study design, data acquisition, analysis and interpretation of data, drafting article, revising article, final approval.
2. Vincent J Kabbaz. Study design, data acquisition, analysis and interpretation of data, drafting article, revising article, final approval.
3. Christopher R Showalter. Study design, revising article, final approval.

All authors have approved this final masterclass article and included case study.

The authors report no conflict of interest except the Appendix Supplementary Case Study patient is the first author, and the treating therapist is the second author.

Appendix A. Neural and vascular structures commonly compromised by Eagle’s syndrome, along with their function and possible symptoms. The descriptions above are not all encompassing, but rather a collection of most of the functions and some possible consequences from disruption of function. Key: CN = Cranial Nerve. ‘BP’ = blood pressure. ‘HR’ = heart rate. 1. (Goodman et al., 2003), 2. (Lundy-Ekman, 2002), 3. (Câmara and Griessenauer, 2015), 4. (Patel, 2015), 5. (Peitersen, 2002), 6. (Butler, 2000), 7. (Baugh et al., 2013), 8. (Robertson et al., 2012), 9. (Porzionato et al., 2019), 10. (Malik et al., 2015), 11. (Tubbs et al., 2015), 12. (Ylikoski et al., 2017), 13. (Mayo Clinic and Mayo Foundation for Medical Education and Research, 2019), 14. (Eagle, 1949), 15. (Li et al., 2019b), 16. (Kawasaki et al., 2012), 17. (Eagle, 1948), 18. (Dashti et al., 2012), 19. (Chung et al., 2010), 20. (Zamboni et al., 2019), 21. (Ho et al., 2015), 22. (Jayaraman et al., 2012), 23. (Zamboni, 2006)

**CN V: Trigeminal Nerve
Anatomy & Function**

Sensory - face, mouth, tongue, mucous membranes of nose and mouth [1] pain, temperature discriminative touch, proprioception [2]

Sensory - eye, Corneal Blink reflex [2]

Sensory - meninges (dura mater, arachnoid mater, pia mater) [1]

Motor - Masseter reflex, muscles of chewing [2]

Possible symptoms with compression or irritation

Pain, (commonly severe, sharp, stabbing) face and jaw, tongue and teeth, provoked with eating, talking, shaving, teeth brushing, or touch, lasting less than 2 min [2]. Dysfunctional pain, ability to locate/discriminate sensations, and ability to distinguish between hot/cold temperatures face and skull [2]. All cranial nerve somatosensory fibers return to the trigeminal nerve sensory nuclei [3].
Dysfunctional Corneal Blink reflex (closing the eyes to stimulation) [2].
Headache, neurological symptoms, altered consciousness and blood pressure, visual disturbances [1].
Dysfunctional Masseter reflex - jaw doesn’t close. Weakness masseter, temporalis, medial/lateral pterygoid. Opening jaw deviation toward involved side [2].

**CN VII: Facial Nerve
Anatomy & Function**

Autonomic - Pterygopalatine ganglion. Lacrimal and nasomucosal glands [1]. Nose, mouth, upper lip, gums, uvula mucous membranes and orbital glands [4]

Autonomic - Nasolacrimal Reflex. Orbicularis oculi muscle transports tears [5]

Autonomic - Submandibular ganglion. Sublingual and submandibular salivary glands [1]

Sensory - partial external ear [6]

Taste anterior tongue [2]

Motor - facial expression musculature, Blink Reflex -activation eyelid closure [2]

Possible symptoms with compression or irritation

Tear flow abnormalities: Dry eyes (hypolacrimia) 4%, or Epiphora (excessive tearing) 67% of patients with Bell’s Palsy [5]. Dysfunctional secretion of mucus (mucocele).
Loss of Nasolacrimal reflex - tearing in response to stimuli. Dysfunction of medial movement of tears to the lacrimal sac [5].
Hyper or hyposalivation (drooling or dry mouth) [2].
Sensation or pain postauricular (52% of patients with Bell’s Palsy) [5].
Hyperacusis - sensation of louder noises on affected side [7].
Reduced sense of taste: sweet, salt, sour and bitter. Reported by 34% of patients with Bell’s Palsy, objectively positive 80% of patients with Bell’s Palsy [5].
Dysfunctional Blink reflex in response to stimuli [2]. Facial paralysis or incomplete paresis. Difficulty or unable to raise eyebrow, close eye, wrinkle nose, raise the corner of mouth, puff cheeks, press lips firmly together, whistle, clench

(continued on next page)

(continued)

Motor - Stapedius, protective reflex [5]	jaw. Stress with facial paresis: 50% of patients with Bell's palsy believe they had a stroke, 25% believe they have a tumor [5]. Dysfunctional Stapedius reflex in 72% of patients with Bell's Palsy, initial exam. Hearing disorder/pitch difference 14% patients with Bell's Palsy [5].
CN IX: Glossopharyngeal Nerve	
Anatomy & Function	
Autonomic - Motor - Salivation via parotid gland [2]	Dysfunctional secretion of mucus and enzymes. Dry mouth or hypersalivation [2].
Autonomic - Regulation of blood vessel dilation in carotid sinus by baroreceptors [1]	Dysfunctional control of blood vessel stretch/tone/blood flow changes [3,8], blood pressure [9]. Sensations of warmth, flushing, headache, sweating, heart palpitations and presyncope. Orthostatic hypertension, elevated blood pressure, venous pooling and decreased heart output, heightened risk of stroke [8].
Autonomic - Regulation of blood concentration in carotid body by chemoreceptors/sensors [1]	Dysfunctional sensation from the walls of the carotid body with altered awareness of oxygen, and dysfunctional monitoring of arterial blood pressure [2].
Sensory - Gag Reflex, Swallowing Reflex [2]	Dysfunctional Gag reflex when touched [2].
Sensory - throat, base of tongue, roof of mouth [1]	Severe, stabbing pain unilaterally in throat, roof of mouth, or base of tongue that can radiate to the ear, provoked with yawning, swallowing, chewing, coughing, and can hurt for seconds up to minutes [10].
Taste - posterior tongue [6]	Dysfunctional taste posterior 1/3 of tongue [6].
Motor - stylopharyngeus muscle [11]	Dysfunctional swallowing [2].
CN X: Vagus Nerve	
Anatomy & Function	
Major autonomic/parasympathetic nerve [6]	Of parasympathetic fibers of cranial nerves, 75% travel in the vagus nerve [2]. Afferent fibers make up 80–90% of the vagus nerve [3]. In one study, 73% of patients with tinnitus were determined to have autonomic dysfunction [12].
Autonomic - pharynx, larynx, trachea, esophagus, heart, lungs, bronchi, stomach, liver, pancreas, gallbladder, most of gastrointestinal tract [2,3]	Loss of regulation of viscera, peristalsis stomach, intestines/appendix/colon. Loss of glandular secretion gastric, adrenal, hepatic, pancreatic [3]. Cardiac arrhythmias. Respiratory dysfunction [2].
Autonomic - heart cardiac muscle, cardiac and pulmonary plexus, and aortic body [3]	Orthostatic hypotension, dizziness, lightheadedness, blurred, dimmed, or tunnel vision, syncope, confusion, cardiac symptoms, angina, tremor, unsteadiness, lethargy, weakness, low backache, calf claudication [1,2]. Heightened sympathetic activity may cause arrhythmia, high blood pressure, hyperglycemia, temperature elevation, or neurogenic pulmonary edema [8], reduced digestive activity [2]. Vasovagal syncope, including clamminess, sweating, pale skin, yawning, vision changes, bradycardia, salivation, pupil dilation [2,13].
Autonomic - Regulation of blood vessel dilation in aortic arch by baroreceptors [3]	Loss of regulation of the walls of the aortic arch with altered regulation in response to vessel stretch/tone/blood flow changes [3,8]. Sensations of warmth, flushing, headache, sweating, heart palpitations and presyncope. Orthostatic hypertension, elevated blood pressure, venous pooling and decreased heart output, heightened risk of stroke [8].
Autonomic - Regulation of blood concentration in carotid body and aortic body by response to chemoreceptors/sensors [3]	Loss of regulation of the walls of the carotid body and aortic body with altered awareness [3] of oxygen in response to sensors [2]. Dysfunctional heart rate regulation in response to concentration changes [3]. Blood pools when vessel walls are relaxed, and can lessen return of blood supply to brain upon standing, leading to syncope or presyncope [2].
Sensory - posterior meninges (dura, pia, & arachnoid mater) [3], posterior ear [1]	Headache, neurological symptoms, altered consciousness and blood pressure, visual disturbances [1]. Dysfunctional pain, touch, temperature sensation [3]
Motor - Gag reflex, Coughing reflex, Sneezing reflex, Yawning reflex, Hiccups reflex [3]	Paralysis or paresis of vocal cords with hoarseness or loss of voice, dysphonia [3], shortness of breath when speaking. Loss of Gag reflex, uvula deviation with inability to raise soft palate [2]. Dysfunctional reflexes coughing, sneezing, yawning, hiccups [3].
Motor - Pharynx and larynx muscles. Swallowing reflex [2]	Difficulty swallowing and elevating the roof of mouth when swallowing. Difficulty speaking initiating sound from the larynx, and expression of sound [2].
Internal Carotid Artery (ICA)	
Anatomy & Function	
Supplies blood to brain	Stenosis, clot, embolus, aneurysm, dissection, TIA, stroke, changing blood flow to the brain, vasculitis, fever [1]. Severe headache one side of the head, (parietal, top of head, frontal, eye, nose), jaw pain, carotidynia [14]. Syncope, presyncope, vision changes, dimmed vision, slurred speech, difficulty speaking [1], lower cranial nerve dysfunction. Horner's syndrome, ptosis (drooping eyelid), constriction of the pupil, loss of sweating over the ipsilateral face [1], upper/lower extremity paresthesias [15]. Weakness or paralysis of face, arm or leg, dizziness, unsteadiness, or falls [1]. Cognitive and behavior changes with decreased blood to the brain, confusion, concentration. Orthostatic hypotension, dizziness, blurred or dimmed vision, syncope, confusion, cardiac symptoms, angina, tremor, unsteadiness, lethargy, weakness, low backache, calf claudication [1].

(continued on next page)

(continued)

External Carotid Artery (ECA) Anatomy & Function		Possible symptoms with compression or irritation
Supplies blood to neck, face, trachea, larynx		Stenosis, clot, embolus, aneurysm, dissection, TIA, stroke changing blood flow to the brain vasculitis, fever [1]. Severe headache one side of the head (below level of eye- neck face, suboccipital), jaw pain, neck pain [14] Lower cranial nerve dysfunctions. Syncope, presyncope, vision changes, slurred speech, difficulty speaking [1]. Weakness or paralysis of face, arm or leg, dizziness, unsteadiness, or falls [1]. Orthostatic hypotension, dizziness, vision changes, syncope, confusion, cardiac symptoms, angina, tremor, unsteadiness, lethargy, weakness, low backache, calf claudication [1].
Periarterial Sympathetic Nerve Fibres/Plexus Structure Anatomy & Function		Possible symptoms with compression or irritation
Carotid Sinus	Baroreceptors on carotid sinus regulate blood pressure, elicits sympatho-inhibition [9] - decreases BP, HR	Dizziness, presyncope, syncope, falls, carotid sinus hypersensitivity, carotid sinus syndrome, amnesia, cardio inhibition, decreased heart rate, blood pressure vasodepression variability [9].
Carotid Body	Chemoreceptors on carotid body regulate blood pressure and respiration [8], and stimulate sympatho-activation [9] - increased BP, decreased HR	Dysfunction in stabilizing hypoxia, hypercapnia and pH blood concentration. Dysfunction of immunoreactivity to certain enzymes/substances. Hyperactive peripheral chemoreflex activity (excessive sympathetic activity), hypertension, chronic kidney disease, insulin resistance [9].
Carotid sinus nerve	Carotid sinus nerve communication with glossopharyngeal nerve fibers, vagus nerve fibers, sympathetic trunk fibers, as well as rare communication with hypoglossal nerve and ansa cervicalis communicating fibers [9]	Hemodynamic instability. Increased sympathetic activity, decreased parasympathetic activity can cause vasoconstriction, heart remodeling, and sodium and water retention [9]. Facial congestion, ear fullness [16], tinnitus [12,17]. Hypoglossal nerve dysfunction can present as same side weakness/ deviation of the tongue, with possible swallowing and talking difficulties [2].
Internal Jugular Vein (IJV) Anatomy & Function		Possible symptoms with compression or irritation
Blood drainage from the brain, face and neck Transports blood to the heart Dominant drainage while supine [19,22]		Intracranial venous hypertension in veins and sinuses, venous outflow obstruction, pseudotumor cerebri, thrombosis, stenosis [18], cerebral venous congestion, increased accumulation of venous blood volume [19]. Dilated ventricles CSF spaces, peri-mesencephalic hemorrhage [20]. Headache, visual changes, papilledema, neck and scapula pain, venous stasis [18], dizziness, ear pain [21]. Collateral venous drainage by enlarged veins in proximity to dysfunctional veins [18,22]. Risk factor for Multiple Sclerosis (MS)[23], global amnesia [22], migraines [19] 30% of undiagnosed patients obtaining CT neck and head had moderate to severe narrowing of the IJV caused by, or in part by the styloid, (symptoms unknown) (Jayaraman et al., 2012). Increased IJV stiffness and reduced venodilation with difficulty compensating for the increased pressure from Valsalva pressure in patients with migraine, resulting in cerebral venous hypertension [19]. Increased venous tone by increased venous pressure with increased sympathetic activity, such as menstruation and hormone fluctuation, environmental factors, stress, fatigue, alcohol intake, sleep disturbances [19]. Production of venous reflux from the chest into the IJV with coughing [23]. Inflammation of vein after faulty venous function [23].

Appendix A. Supplementary Case Study

Supplementary data to this article can be found online at <https://doi.org/10.1016/j.msksp.2020.102219>.

References

- Akasbi, M., Berenguer, J., Saiz, A., Brito-Zerón, P., Pérez-De-Lis, M., Bové, A., Diaz-Lagares, C., Retamozo, S., Blanco, Y., Perez-Alvarez, R., Bosch, X., Sisó, A., Graus, F., Ramos-Casals, M., 2012. White matter abnormalities in primary Sjögren syndrome. *QJM* 105, 433–443. <https://doi.org/10.1093/qjmed/hcr218>.
- Aydin, E., Quliyev, H., Cinar, C., Bozkaya, H., Oran, I., 2018. Eagle syndrome presented with neurological symptoms. *Turk. Neurosurg.* 28, 219–225. <https://doi.org/10.5137/1019-5149.JTN.17905-16.6>.
- Badhey, A., Jategaonkar, A., Anglin Kovacs, A.J., Kadakia, S., De Deyn, P.P., Ducic, Y., Schantz, S., Shin, E., 2017. Eagle syndrome: a comprehensive review. *Clin. Neurol. Neurosurg.* 159, 34–38. <https://doi.org/10.1016/j.clineuro.2017.04.021>.
- Barral, J.P., Croibier, A., 2009. Manual therapy for the cranial nerves. In: *Manual Therapy for the Cranial Nerves*. Elsevier, pp. 153–166. <https://doi.org/10.1016/C2009-0-38538-4>.
- Baugh, R.F., Basura, G.J., Ishii, L.E., Schwartz, S.R., Drumheller, C.M., Burkholder, R., Deckard, N.A., Dawson, C., Driscoll, C., Gillespie, M.B., Gurgel, R.K., Halperin, J., Khalid, A.N., Kumar, K.A., Micco, A., Munsell, D., Rosenbaum, S., Vaughan, W., 2013. Clinical practice guideline: Bell's palsy. *Otolaryngol. Neck Surg.* 149, S1–S27. <https://doi.org/10.1177/0194599813505967>.
- Bensoussan, Y., Letourneau-Guillon, L., Ayad, T., 2014. Atypical presentation of Eagle syndrome with hypoglossal nerve palsy and Horner syndrome. *Head Neck* 36, E136–E138. <https://doi.org/10.1002/hed.23675>.
- Budinčević, H., Milošević, M., Pavlović, T., 2018. Giant pseudoaneurysm of the external carotid artery causing stroke: a case report. *J. Clin. Ultrasound* 46, 269–272. <https://doi.org/10.1002/jcu.22524>.
- Butler, D., 2000. *The Sensitive Nervous System*. Noigroup Publications, Adelaide, Australia.
- Câmara, R., Griessenauer, C.J., 2015. Anatomy of the vagus nerve. In: *Nerves and Nerve Injuries*. Elsevier, pp. 385–397. <https://doi.org/10.1016/B978-0-12-410390-0.00028-7>.
- Ceylan, A., Köybaşıoğlu, A., Çelenk, F., Yılmaz, O., Uslu, S., 2008. Surgical treatment of elongated styloid process: experience of 61 cases. *Skull Base* 18, 289–295. <https://doi.org/10.1055/s-0028-1086057>.
- Chang, C.A., Lin, T., Fung, K., Sharma, M., Fraser, J.A., 2015. Isolated horner syndrome from an elongated styloid process (eagle syndrome). *J. Neuro Ophthalmol.* 35, 387–389. <https://doi.org/10.1097/WNO.0000000000000260>.
- Chuang, W.C., Short, J.H., McKinney, A.M., Anker, L., Knoll, B., McKinney, Z.J., 2007. Reversible left hemispheric ischemia secondary to carotid compression in Eagle syndrome: surgical and CT angiographic correlation. *AJNR. Am. J. Neuroradiol.* 28, 143–145.

- Chung, C.P., Chao, A.C., Hsu, H.Y., Lin, S.J., Hu, H.H., 2010. Decreased jugular venous distensibility in migraine. *Ultrasound Med. Biol.* 36, 11–16. <https://doi.org/10.1016/j.ultrasmedbio.2009.08.007>.
- Cleland, J.A., Childs, M.J.D., McRae, M., Palmer, J.A., Stowell, T., 2005. Immediate effects of thoracic manipulation in patients with neck pain: a randomized clinical trial. *Man. Ther.* 10, 127–135. <https://doi.org/10.1016/j.math.2004.08.005>.
- Correll, R.W., Jensen, J.L., Taylor, J.B., Rhyne, R.R., 1979. Mineralization of the stylohyoid-stylomandibular ligament complex. *Oral Surgery. Oral Med. Oral Pathol.* 48, 286–291. [https://doi.org/10.1016/0030-4220\(79\)90025-2](https://doi.org/10.1016/0030-4220(79)90025-2).
- Costantinides, F., Della Flora, F., Tonni, I., Bodin, C., Bazzocchi, G., Artero, M.L., Castronovo, G., Vettori, E., Nicolini, V., Di Lenarda, R., 2019. Elongation of the styloid processes in kidney-transplanted patients: the role of ectopic calcification as possible cause of Eagle syndrome. *CRANIO®* 1–5. <https://doi.org/10.1080/08869634.2019.1640919>.
- Costantinides, F., Vidoni, G., Bodin, C., Di Lenarda, R., 2013. Eagle's syndrome: signs and symptoms. *CRANIO®* 31, 56–60. <https://doi.org/10.1179/crn.2013.008>.
- Dashti, S.R., Nakaji, P., Hu, Y.C., Frei, D.F., Abla, A.A., Yao, T., Fiorella, D., Ogungbo, B., 2012. Styloidyogenic jugular venous compression syndrome: diagnosis and treatment: case report. *Neurosurgery* 70. <https://doi.org/10.1227/NEU.0b013e3182333859>, 783–783.
- David, J., Lieb, M., Rahimi, S.A., 2014. Stylocarotid artery syndrome. *J. Vasc. Surg.* 60, 1661–1663. <https://doi.org/10.1016/j.jvs.2014.05.048>.
- Dayal, V., Morrison, M., Dickson, T., 1971. Elongated styloid process. *Arch. Otolaryngol.* 94, 174–175.
- Douglas, T.E., 1952. Facial pain from elongated styloid process. *Arch. Otolaryngol. Head Neck Surg.* 56, 635–638. <https://doi.org/10.1001/archotol.1952.00710020660007>.
- Eagle, W.W., 1958. Elongated styloid process: symptoms and treatment. *Arch. Otolaryngol. Head Neck Surg.* 67, 172–176. <https://doi.org/10.1001/archotol.1958.00730010178007>.
- Eagle, W.W., 1949. Symptomatic elongated styloid process: report of two cases of styloid process-carotid artery syndrome with operation. *Arch. Otolaryngol. Head Neck Surg.* 49, 490–503. <https://doi.org/10.1001/archotol.1949.03760110046003>.
- Eagle, W.W., 1948. Elongated styloid process: further observations and a new syndrome. *Arch. Otolaryngol. Head Neck Surg.* 47, 630–640. <https://doi.org/10.1001/archotol.1948.00690030654006>.
- Eraslan, C., Ozer, M.A., Govsa, F., Alagoz, A.K., Calli, C., 2017. Relationship of stylohyoid chain and cervical internal carotid artery detected by 3D angiography. *Surg. Radiol. Anat.* 39, 897–904. <https://doi.org/10.1007/s00276-017-1812-4>.
- Ernst, E., 2004. Cerebrovascular complications associated with spinal manipulation. *Phys. Ther. Rev.* 9, 5–15. <https://doi.org/10.1179/108331904225003946>.
- Faivre, A., Abdelfettah, Z., Rodriguez, S., Nicolini, F., 2009. Bilateral internal carotid artery dissection due to elongated styloid processes and shaking dancing. *Neurosurg. Psychiatry* 80, 1154–1155. <https://doi.org/10.1136/jnnp.2008.159954>.
- Feldman, V., 2003. Eagle's syndrome: a case of symptomatic calcification of the stylohyoid ligaments. *J. Can. Chiropr. Assoc.* 47, 21–27.
- Frommer, J., 1974. Anatomic variations in the stylohyoid chain and their possible clinical significance. *Oral Surgery. Oral Med. Oral Pathol.* 38, 659–667. [https://doi.org/10.1016/0030-4220\(74\)90382-X](https://doi.org/10.1016/0030-4220(74)90382-X).
- Galletta, K., Siniscalchi, E.N., Cicciù, M., Velo, M., Granata, F., 2019. Eagle syndrome: a wide spectrum of clinical and neuroradiological findings from cervico-facial pain to cerebral ischemia. *J. Craniofac. Surg.* 30, E424–E428. <https://doi.org/10.1097/SCS.00000000000005453>.
- Ge, Y., Law, M., Johnson, G., et al., 2005. Dynamic susceptibility contrast perfusion MR imaging of multiple sclerosis lesions: characterizing hemodynamic impairment and inflammatory activity. *Am. J. Neuroradiol.* 26, 1539–1547.
- Goldstein, G.R., Scopp, I.W., 1973. Radiographic interpretation of calcified stylohyoid ligament and stylohyoid ligaments. *J. Prosthet. Dent* 30, 330–334. [https://doi.org/10.1016/0022-3913\(73\)90192-3](https://doi.org/10.1016/0022-3913(73)90192-3).
- Goodman, C., Boissonnault, W., Fuller, K., 2003. *Pathology: Implications for the Physical Therapist, Second Edition*. Elsevier Science, USA.
- Green, B.N., Broske, L.K.M., Rosenthal, C.M.D., 2014. Elongated styloid processes and calcified stylohyoid ligaments in a patient with neck pain: implications for manual therapy practice. *J. Chiropr. Med.* 13, 128–133. <https://doi.org/10.1016/j.jcm.2014.06.006>.
- Hampf, G., Aalberg, V., Tasanen, A., Nyman, C., 1986. A holistic approach to stylalgia. *Int. J. Oral Maxillofac. Surg.* 15, 549–552. [https://doi.org/10.1016/S0300-9785\(86\)80057-6](https://doi.org/10.1016/S0300-9785(86)80057-6).
- Higgins, J., Garnett, M., Pickard, J., Xiong, P., 2016. An evaluation of styloideotomy as an adjunct or alternative to jugular stenting in idiopathic intracranial hypertension and disturbances of cranial venous outflow. *J. Neurol. Surg. Part B Skull Base* 78, 158–163. <https://doi.org/10.1055/s-0036-1594238>.
- Ho, S., Luginbuhl, A., Finden, S., Curry, J.M., Cognetti, D.M., 2015. Styloid/C1 transverse process juxtaposition as a cause of Eagle's syndrome. *Head Neck* 37, E153–E156. <https://doi.org/10.1002/hed.24024>.
- Holey, L.A., Dixon, J., Selve, J., 2011. An exploratory thermographic investigation of the effects of connective tissue massage on autonomic function. *J. Manip. Physiol. Ther.* 34, 457–462. <https://doi.org/10.1016/j.jmpt.2011.05.012>.
- Jayaraman, M.V., Boxerman, J.L., Davis, L.M., Haas, R.A., Rogg, J.M., 2012. Incidence of extrinsic compression of the internal jugular vein in unselected patients undergoing CT angiography. *Am. J. Neuroradiol.* 33, 1247–1250. <https://doi.org/10.3174/ajnr.A2953>.
- Jelodar, S., Ghadirian, H., Ketabchi, M., Ahmadi Karvigh, S., Alimohamadi, M., 2018. Bilateral ischemic stroke due to carotid artery compression by abnormally elongated styloid process at both sides: a case report. *J. Stroke Cerebrovasc. Dis.* 27, e89–e91. <https://doi.org/10.1016/j.jstrokecerebrovasdis.2017.12.018>.
- Johnson, G.M., Rosdy, N.M., Horton, S.J., 2011. Manual therapy assessment findings in patients diagnosed with Eagle's Syndrome: a case series. *Man. Ther.* 16, 199–202. <https://doi.org/10.1016/j.math.2010.09.007>.
- Kapoor, V., Jindal, G., Garg, S., 2015. Eagle's syndrome: a new surgical technique for styloideotomy. *J. Maxillofac. Oral Surg.* 14, 360–365. <https://doi.org/10.1007/s12663-013-0597-1>.
- Kaufman, S.M., Elzay, R.P., Irish, E.F., 1970. Styloid process variation: radiologic and clinical study. *Arch. Otolaryngol.* 91, 460–463. <https://doi.org/10.1001/archotol.1970.00770040654013>.
- Kawasaki, M., Hatashima, S., Matsuda, T., 2012. Non-surgical therapy for bilateral glossopharyngeal neuralgia caused by Eagle's syndrome, diagnosed by three-dimensional computed tomography: a case report. *J. Anesth.* 26, 918–921. <https://doi.org/10.1007/s00540-012-1437-z>.
- Kerry, R., Taylor, A.J., 2006. Cervical arterial dysfunction assessment and manual therapy. *Man. Ther.* 11, 243–253. <https://doi.org/10.1016/j.math.2006.09.006>.
- Keur, J.J., Campbell, J.P.S., McCarthy, J.F., Ralph, W.J., 1986. The clinical significance of the elongated styloid process. *Oral Surgery. Oral Med. Oral Pathol.* 61, 399–404. [https://doi.org/10.1016/0030-4220\(86\)90426-3](https://doi.org/10.1016/0030-4220(86)90426-3).
- Khan, S., Schoenen, J., Ashina, M., 2014. Sphenopalatine ganglion neuromodulation in migraine: what is the rationale? *Cephalalgia* 34, 382–391. <https://doi.org/10.1177/0333102413512032>.
- Khonsary, S., Ma, Q., Villablanca, P., Emerson, J., Malkasian, D., 2013. Clinical dysfunction anatomy of the pterygopalatine ganglion, cephalgia and related dysautonomias: a review. *Surg. Neurol. Int.* 4, 422. <https://doi.org/10.4103/2152-7806.121628>.
- Krohn, S., Brockmeyer, P., Kubein-Meesenburg, D., Kirschneck, C., Buegers, R., 2018. Elongated styloid process in patients with temporomandibular disorders — is there a link? *Ann. Anat.* 217, 118–124. <https://doi.org/10.1016/j.aanat.2018.01.007>.
- Levy, T., Bader, S., Hermann, K.G., Yaniv, G., Grinberg, G., Mozes, O., Lidar, M., Eshed, I., 2017. Styloid process elongation on cervical spine computed tomography is associated with the enthesopathy-related diseases in ankylosing spondylitis and diffuse idiopathic skeletal hyperostosis. *Isr. Med. Assoc. J.* 19, 670–673.
- Li, M., Sun, Y., Chan, C.C., Fan, C., Ji, X., Meng, R., 2019a. Internal jugular vein stenosis associated with elongated styloid process: five case reports and literature review. *BMC Neurol.* 19, 112. <https://doi.org/10.1186/s12883-019-1344-0>.
- Li, Z., Hua, Y., Yang, J., Li, J., 2019b. Ultrasound evaluation of transient ischemic attack caused by styloid process elongation: a case report. *Front. Neurol.* 10, 1–6. <https://doi.org/10.3389/fneur.2019.00026>.
- Lundy-Ekman, L., 2002. *Neuroscience - Fundamentals for Rehabilitation, second ed.* Saunders Company, Philadelphia, PA.
- Maki, D., Okami, K., Ebisumoto, K., Sakai, A., 2018. Chronological progression of an enlarged styloid process: a case report of eagle syndrome. *Case Rep. Otolaryngol.* 1–4. <https://doi.org/10.1155/2018/9207264>, 2018.
- Malik, Y., Dar, J.A., Almadani, A.A.R., 2015. Seizures with an atypical aetiology in an elderly patient: eagle's syndrome-how does one treat it? *BMJ Case Rep.* 10–13. <https://doi.org/10.1136/bcr-2014-206136>, 2015.
- Massey, E.W., Massey, J., 1979. Elongated styloid process (Eagle's Syndrome) Causing Hemiparesis. *Headache J. Head Face Pain* 19, 339–344. <https://doi.org/10.1111/j.1526-4610.1979.hed1906339.x>.
- Mayo Clinic, Mayo Foundation for Medical Education and Research, 2019. Vasovagal Syncope [on-line publication]. *Mayo Clin. URL www.mayoclinic.org/diseases-conditions/vasovagal-syncope/symptoms-causes/syc-20350527?p=1*.
- Morrison, P.J., Morrison, R.J., McKinstry, C.S., 2012. Familial ossification of the stylohyoid ligament in a three generation family - A new clinical entity displaying autosomal dominant inheritance. *Br. J. Radiol.* 85, 458–459. <https://doi.org/10.1259/bjr/21631652>.
- Nayak, D.R., Pujary, K., Aggarwal, M., Punnoose, S.E., Chaly, V.A., 2007. Role of three-dimensional computed tomography reconstruction in the management of elongated styloid process: A preliminary study. *J. Laryngol. Otol.* 121, 349–353. <https://doi.org/10.1017/S0022215106003276>.
- Nturibi, E., Bordini, B., 2020. *Anatomy, Head and Neck, Greater Petrosal Nerve-StatPearls*. StatPearls Publishing, Treasure Island (FL).
- Ogura, T., Mineharu, Y., Todo, K., Kohara, N., Sakai, N., 2015. Carotid Artery Dissection Caused by an Elongated Styloid Process: Three Case Reports and Review of the Literature. *NMC Case Rep. J.* 2, 21–25. <https://doi.org/10.2176/nmcrrj.2014-0179>.
- Papaharilaou, Y., Aristokleous, N., Seimenis, I., Khozayemeh, M.I., Georgiou, G.C., Brott, B.C., Eracleous, E., Anayiotos, A.S., 2013. Effect of head posture on the healthy human carotid bifurcation hemodynamics. *Med. Biol. Eng. Comput.* 51, 207–218. <https://doi.org/10.1007/s11517-012-0985-6>.
- Patel, T.R., 2015. Anatomy of the Sympathetic Nervous System. In: *Nerves and Nerve Injuries*. Elsevier, pp. 495–506. <https://doi.org/10.1016/B978-0-12-410390-0.00038-X>.
- Peitersen, E., 2002. Bell's Palsy: The Spontaneous Course of 2,500 Peripheral Facial Nerve Palsies of Different Etiologies. *Acta Otolaryngol Suppl* 549, 4–30.
- Piagkou, M.N., Anagnostopoulou, S., Kouladouras, K., Piagkos, G., 2009. Eagle's syndrome: A review of the literature. *Clin. Anat.* 22, 545–558. <https://doi.org/10.1002/ca.20804>.
- Porzionato, A., Macchi, V., Stecco, C., De Caro, R., 2019. The Carotid Sinus Nerve—Structure, Function, and Clinical Implications. *Anat. Rec.* 302, 575–587. <https://doi.org/10.1002/ar.23829>.
- Prasad, K.C., Kamath, M.P., Reddy, K.J.M., Raju, K., Agarwal, S., 2002. Elongated styloid process (Eagle's syndrome): A clinical study. *J. Oral Maxillofac. Surg.* 60, 171–175. <https://doi.org/10.1053/joms.2002.29814>.
- Qureshi, S., Farooq, M.U., Gorelick, P.B., 2019. Ischemic Stroke Secondary to Stylocarotid Variant of Eagle Syndrome. *Neurohospitalist* 9, 105–108. <https://doi.org/10.1177/1941874418797763>.

- Ramadan, S.U., Gokharman, D., Tunçbilek, I., Kacar, M., Koşar, P., Kosar, U., 2007. Assessment of the stylohyoid chain by 3D-CT. *Surg. Radiol. Anat.* 29, 583–588. <https://doi.org/10.1007/s00276-007-0239-8>.
- Raser, J.M., Mullen, M.T., Kasner, S.E., Cucchiara, B.L., Messé, S.R., 2011. Cervical carotid artery dissection is associated with styloid process length. *Neurology* 77, 2061–2066. <https://doi.org/10.1212/WNL.0b013e31823b4729>.
- Razak, A., Short, J.L., Hussain, S.I., 2014. Carotid artery dissection due to elongated styloid process: A self-stabbing phenomenon. *J. Neuroimaging* 24, 298–301. <https://doi.org/10.1111/j.1552-6569.2012.00759.x>.
- Ringel, S.P., Harrison, S.H., Norenberg, M.D., Austin, J.H., 1977. Fibromuscular dysplasia: Multiple “spontaneous” dissecting aneurysms of the major cervical arteries. *Ann. Neurol.* 1, 301–304. <https://doi.org/10.1002/ana.410010320>.
- Rivett, D., Sharples, K., Milburn, P., 1999. Effect of premanipulative tests on vertebral artery and internal carotid artery blood flow: A pilot study. *J. Manip. Physiol. Ther.* 22, 368–375. [https://doi.org/10.1016/S0161-4754\(99\)70081-3](https://doi.org/10.1016/S0161-4754(99)70081-3).
- Rivett, D., Shirley, D., Magarey, M., Refshauge, K., 2006. Clinical Guidelines for Assessing Vertebrobasilar Insufficiency in the Management of Cervical Spine Disorders. *Aust. Physiother. Assoc.* 1–14.
- Robertson, D., Biaggioni, I., Burnstock, G., et al., 2012. *Primer on the Autonomic Nervous System*, Third. ed. Academic Press, Elsevier.
- Robertson, D., Kincaid, D.W., Haile, V., Robertson, R.M., 1994. The head and neck discomfort of autonomic failure: An unrecognized aetiology of headache. *Clin. Auton. Res.* 4, 99–103. <https://doi.org/10.1007/BF01845772>.
- Rushton, A., Rivett, D., Carlesso, L., Flynn, T., Hing, W., Kerry, R., 2014. International framework for examination of the cervical region for potential of Cervical Arterial Dysfunction prior to Orthopaedic Manual Therapy intervention. *Man. Ther.* 19, 222–228. <https://doi.org/10.1016/j.math.2013.11.005>.
- Ruwampura, P.R., Abeygunasekera, A.M., Tikiri, G.K.M.B., 2008. Sudden unexpected death probably due to Eagle’s syndrome. *Med. Sci. Law* 48, 350–353. <https://doi.org/10.1258/rsmmsl.48.4.350>.
- Saccomanno, S., Greco, F., De Corso, E., Lucidi, D., Deli, R., D’Addona, A., Paludetti, G., 2018. Eagle’s syndrome, from clinical presentation to diagnosis and surgical treatment: A case report. *Acta Otorhinolaryngol. Ital.* 38, 166–169. <https://doi.org/10.14639/0392-100X-1479>.
- Scavone, G., Caltabiano, D.C., Raciti, M.V., Calcagno, M.C., Pennisi, M., Musumeci, A.G., Ettorre, G.C., 2019. Eagle’s syndrome: a case report and CT pictorial review. *Radiol. Case Reports* 14, 141–145. <https://doi.org/10.1016/j.radcr.2018.10.008>.
- Schmidt, O.V.M., 1951. Elongated Styloid Process Which Interfered With Function of a Singer’s Voice: Operation and Recovery. *Arch. Otolaryngol. Head Neck Surg.* 54, 417–421. <https://doi.org/10.1001/archotol.1951.03750100079009>.
- Shenoi, P.M., 1972. Stylohyoid syndrome. *J. Laryngol. Otol.* 86, 1203–1211. <https://doi.org/10.1017/S0022215100076428>.
- Shin, J.H., Herrera, S.R., Eboli, P., Aydin, S., Eskandar, E.H., Slavin, K.V., 2009. Entrapment of the glossopharyngeal nerve in patients with Eagle syndrome: Surgical technique and outcomes in a series of 5 patients: Clinical article. *J. Neurosurg.* 111, 1226–1230. <https://doi.org/10.3171/2009.1.JNS08485>.
- Singhania, A.A., Chauhan, N.V., George, A., Rathwala, K., 2013. Lidocaine Infiltration Test: An Useful Test in the Prediction of Results of Styloidectomy for Eagle’s Syndrome. *Indian J. Otolaryngol. Head Neck Surg.* 65, 20–23. <https://doi.org/10.1007/s12070-012-0577-7>.
- Slavin, K.V., 2002. Eagle syndrome: Entrapment of the glossopharyngeal nerve? Case report and review of the literature. *J. Neurosurg.* 97, 216–218. <https://doi.org/10.3171/jns.2002.97.1.0216>.
- Soo, O.Y.Y., Chan, Y.L., Wong, K.S., 2004. Carotid artery dissection after prolonged head tilting while holding a newborn baby to sleep. *Neurology* 62, 1647–1648. <https://doi.org/10.1212/01.WNL.0000123016.81648.B6>.
- Steinmann, E.P., 1970. A New Light on the Pathogenesis of the Styloid Syndrome. *Arch. Otolaryngol.* 91, 171–174. <https://doi.org/10.1001/archotol.1970.00770040241013>.
- Subedi, R., Dean, R., Barons, S., Dhamoon, A., 2017. Carotid artery dissection: a rare complication of Eagle syndrome. *BMJ Case Rep.* <https://doi.org/10.1136/bcr-2016-218184>.
- Sultan, S., Elkady, R., Barrett, N., Hynes, N., 2019. Endovascular management of sacular extracranial internal carotid artery aneurysm using transcervical carotid approach and flow reversal. *J. Vasc. Surg. Cases Innov. Tech.* 5, 273–277. <https://doi.org/10.1016/j.jvsct.2019.03.013>.
- Sveinsson, O., Kostulas, N., Herrman, L., 2013. Internal carotid dissection caused by an elongated styloid process (Eagle syndrome). *Case Reports* 2013, bcr2013009878–bcr2013009878. <https://doi.org/10.1136/bcr-2013-009878>.
- Swartz, R.H., Kern, R.Z., 2004. Migraine is associated with magnetic resonance imaging white matter abnormalities: A meta-analysis. *Arch. Neurol.* 61, 1366–1368. <https://doi.org/10.1001/archneur.61.9.1366>.
- Takino, T., Shibuma, S., Kanemaru, Y., Okamura, K., 2018. Bilateral Internal Carotid Artery Dissection Caused by Elongated Styloid Processes: A Case Report. *Noshinkeigeka* 46, 53–59. <https://doi.org/10.11477/mf.1436203675>.
- Thoenissen, P., Bittermann, G., Schmelzeisen, R., Oshima, T., Fretwurst, T., 2015. Eagle’s syndrome—A non-perceived differential diagnosis of temporomandibular disorder. *Int. J. Surg. Case Rep.* 15, 123–126. <https://doi.org/10.1016/j.ijscr.2015.08.036>.
- Thomas, L.C., 2016. Cervical arterial dissection: An overview and implications for manipulative therapy practice. *Man. Ther.* 21, 2–9. <https://doi.org/10.1016/j.math.2015.07.008>.
- Todo, T., Alexander, M., Stokol, C., Lyden, P., Braunstein, G., Gewertz, B., 2012. Eagle syndrome revisited: Cerebrovascular complications. *Ann. Vasc. Surg.* 26 <https://doi.org/10.1016/j.avsg.2011.12.005>, 729.e1–729.e5.
- Torikoshi, S., Yamao, Y., Ogino, E., Taki, W., Sunohara, T., Nishimura, M., 2019. A Staged Therapy for Internal Carotid Artery Dissection Caused by Vascular Eagle Syndrome. *World Neurosurg* 129, 133–139. <https://doi.org/10.1016/j.wneu.2019.05.208>.
- Tubbs, R.S., Loukas, M., Dixon, J., Cohen-Gadol, A.A., 2010. Compression of the cervical internal carotid artery by the stylopharyngeus muscle: An anatomical study with potential clinical significance: Laboratory investigation. *J. Neurosurg.* 113, 881–884. <https://doi.org/10.3171/2010.1.JNS091407>.
- Tubbs, R.S., Shoja, M.M., Loukas, M., 2015. Anatomy of the Glossopharyngeal Nerve. In: *Nerves and Nerve Injuries*. Elsevier, pp. 371–383. <https://doi.org/10.1016/B978-0-12-410390-0.00027-5>.
- Umeda, S., Harrison, N.A., Gray, M.A., Mathias, C.J., Critchley, H.D., 2015. Structural brain abnormalities in postural tachycardia syndrome: A VBM-DARTEL study. *Front. Neurosci.* 9, 1–8. <https://doi.org/10.3389/fnins.2015.00034>.
- Wang, X., Chatchawan, U., Nakmareong, S., Silsirivanit, A., Wang, Y., Xie, D., Yang, J., Eungpinichpong, W., 2015. Effects of GUASHA on Heart Rate Variability in Healthy Male Volunteers under Normal Condition and Weightlifters after Weightlifting Training Sessions. *Evidence-Based Complement. Altern. Med.* 1–6. <https://doi.org/10.1155/2015/268471>, 2015.
- Waters, C.M., Ho, S., Luginbuhl, A., Curry, J.M., Cognetti, D.M., 2019. Surgical Management of Stylohyoid Pain (Eagle’s) Syndrome: A 5-Year Experience. *Ann. Otol. Rhinol. Laryngol.* 128, 220–226. <https://doi.org/10.1177/0003489418816999>.
- Westbrook, A., Kabbaz, V., Showalter, C., 2019. Cervical Hypomobility or Sinister Pathology: A Case Report on Eagle’s Syndrome. In: *AAOMPT Poster Presentation*. Orlando, FL.
- Willett, G.M., Walker, T.F., Norton, N.S., 2019. Stylohyoid syndrome. *J. Orthop. Sports Phys. Ther.* 49, 621. <https://doi.org/10.2519/jospt.2019.8759>.
- Wong, M.L., Rossi, M.D., Groff, W., Castro, S., Powell, J., 2011. Physical therapy management of a patient with Eagle syndrome. *Physiother. Theory Pract.* 27, 319–327. <https://doi.org/10.3109/09593985.2010.498036>.
- Yamamoto, S., Todo, K., Kawamoto, M., Kohara, N., 2013. Carotid Artery Dissection Associated with an Elongated Styloid Process. *Intern. Med.* 52, 1005–1006. <https://doi.org/10.2169/internalmedicine.52.0024>.
- Yilmaz, M.T., Akin, D., Cicekcibasi, A.E., Kabakci, A.D.A., Seker, M., Sakarya, M.E., 2015. Morphometric analysis of styloid process using multidetector computed tomography. *J. Craniofac. Surg.* 26, e438–e443. <https://doi.org/10.1097/SCS.0000000000001888>.
- Ylikoski, J., Lehtimäki, J., Pirvola, U., Mäkitie, A., Aarnisalo, A., Hyvärinen, P., Ylikoski, M., 2017. Non-invasive vagus nerve stimulation reduces sympathetic preponderance in patients with tinnitus. *Acta Otolaryngol.* 137, 426–431. <https://doi.org/10.1080/00016489.2016.1269197>.
- Zamboni, P., 2006. The Big Idea: Iron-dependent inflammation in venous disease and proposed parallels in multiple sclerosis. *J. R. Soc. Med.* 99, 589–593. <https://doi.org/10.1258/jrsm.99.11.589>.
- Zamboni, P., Scerrati, A., Menegatti, E., Galeotti, R., Lapparelli, M., Traina, L., Tessari, M., Ciorda, A., De Bonis, P., Pelucchi, S., 2019. The eagle jugular syndrome. *BMC Neurol.* 19, 1–7. <https://doi.org/10.1186/s12883-019-1572-3>.
- Zeckler, S.R., Betancur, A.G., Yaniv, G., 2012. The eagle is landing: Eagle syndrome - An important differential diagnosis. *Br. J. Gen. Pract.* 62, 501–502. <https://doi.org/10.3399/bjgp12X654777>.
- Zinnuroglu, M., Ural, A., Günendi, Z., Meray, J., Köybaşıoğlu, A., 2008. Is there a relationship between Eagle Syndrome and cervicofacial painful soft tissue rheumatism? *Laryngoscope* 118, 1569–1573. <https://doi.org/10.1097/MLG.0b013e31817aec95>.
- Zuber, M., Meder, J.F., Mas, J.L., 1999. Carotid artery dissection due to elongated styloid process. *Neurology* 53. <https://doi.org/10.1212/WNL.53.8.1886>, 1886–1886.
- Andrea Westbrook is certified in orthopedic manual therapy and a Fellow of AAOMPT. She is a full-time clinician treating primarily patients with chronic spinal complaints. She presented with symptoms of Eagle’s syndrome and was able to determine the diagnosis after ample research and find alleviation of her symptoms with styloidectomies. She has been able to verify elongated styloid processes in over 20 patients with recalcitrant neck and head symptoms and assist in their referral to ENT providers for proper assessment and treatment after limited lasting benefits to PT interventions. She co-authored and presented a poster on Eagle’s Syndrome in 2019 at AAOMPT.
- Vincent J. Kabbaz is a Master of Manipulative Physiotherapy and Fellow of AAOMPT. He received his Master’s in Manipulative Physiotherapy and Bachelor’s of Applied Science in Physiotherapy from the University of South Australia. He is a Fellowship instructor teaching advanced manual therapy and manipulation assessment and treatment techniques, including precautions and contraindications for cervical arterial dysfunction. He owns HEAL Physical Therapy, specializing in neuromusculoskeletal conditions and detected the elongated styloid process during a routine evaluation of Andrea’s neck during her Fellowship training. Vince has co-authored publications on low back & neck pain, thrust manipulation, Eagle’s syndrome & presented at conferences nationally and in Beirut.
- Christopher Showalter is Doctor of Physical Therapy, an Orthopedic Certified Specialist and Fellow of AAOMPT. He is the Program Director of Maitland-Australian Physiotherapy Seminars (MAPS) orthopedic manual physical therapy fellowship which is accredited by the American Academy of Orthopedic Manual Physical Therapists (AAOMPT). Dr. Westbrook completed this study as partial fulfillment of the research component of the MAPS Fellowship. Dr. Showalter has advised on this project since inception.